

Short-Wavelength Automated Perimetry and Standard Perimetry in the Detection of Progressive Optic Disc Cupping

Christopher A. Girkin, MD; Alireza Emdadi, MD; Pamela A. Sample, PhD;
Eytan Z. Blumenthal, MD; Alex C. Lee, BA; Linda M. Zangwill, PhD; Robert N. Weinreb, MD

Objective: To compare progression in short-wavelength automated perimetry (SWAP) and white-on-white (standard) perimetry in eyes with progressive glaucomatous changes of the optic disc detected by serial stereophotographs.

Methods: Forty-seven glaucoma patients with at least 2 disc stereophotographs more than 2 years apart, along with standard perimetry and SWAP examinations within 6 months of each disc photo of the same eye, were included in the study. The mean follow-up time was 4.1 years (range, 2.0-8.9 years). Baseline and follow-up stereophotographs were then graded and compared for the presence of progression. Progression in standard perimetry and SWAP, using the Advanced Glaucoma Intervention Study scoring system and a clinical scoring system, was compared between eyes with progressive change on stereophotographs and those without.

Results: Twenty-two of 47 eyes showed progressive

change by stereophotographs. There was a statistically significant difference in the mean change in Advanced Glaucoma Intervention Study scores for both standard perimetry ($P < .004$) and SWAP ($P < .001$) between the progressed and nonprogressed groups. The sensitivity, specificity, and area under the receiver operator characteristic curve were higher using SWAP than standard perimetry when evaluated by either algorithm. This was statistically significant only in the area under the receiver operator characteristic curve for the Advanced Glaucoma Intervention Study scoring system ($P = .04$).

Conclusions: Short-wavelength automated perimetry identified more patients than standard perimetry as having progressive glaucomatous changes of the optic disc. Compared with standard perimetry, SWAP may improve the detection of progressive glaucoma.

Arch Ophthalmol. 2000;118:1231-1236

CURRENT METHODS for detection of progressive glaucomatous optic nerve damage rely on clinical examination, including serial stereoscopic examinations of the optic disc, as well as serial evaluations using standard achromatic visual fields. Media opacities and small pupils limit both direct stereoscopic disc evaluation and stereophotographs. Additionally, evaluation of the optic disc is subjective, with significant interexaminer variability.¹⁻³ Assessment of visual fields to detect progression is limited by several factors. These include poor sensitivity,⁴ intertest variability,^{5,6} patient experience, testing fatigue,⁷ media opacities,⁸ pupil size,⁹ test set-up, and the subject's level of attention.¹⁰

Because of the limitations of white-on-white (standard) perimetry in the diagnosis of early glaucoma, there is considerable interest in developing more

sensitive measures of visual function. One such technique is short-wavelength automated perimetry (SWAP), which selectively isolates the S-cone responses in the central visual field.¹¹ The short-wavelength-sensitive pathways mediate the S-cone signal via the bistratified subpopulation of ganglion cells.¹² Short-wavelength automated perimetry uses a 2-color increment threshold procedure that presents a blue stimulus, which preferentially stimulates the short-wavelength-sensitive pathway, against a yellow background. This background saturates the rods and suppresses the sensitivity of the long- and medium-wavelength pathways.¹¹

Short-wavelength automated perimetry has been shown to be more sensitive than standard perimetry in detecting early glaucomatous optic nerve damage.^{13,14} The selective nature of the SWAP stimuli may increase its ability to detect progression, even in advanced disease.¹⁵ Additionally, visual field defects detected using SWAP

From the Glaucoma Center,
University of California–San
Diego, La Jolla.

PATIENTS AND METHODS

PATIENTS

We reviewed 382 records of patients diagnosed as having an optic disc appearance consistent with glaucoma, based on masked grading of optic disc stereophotographs (cup-disc ratio >0.7 , cup-disc ratio asymmetry ≥ 0.2 , rim thinning, excavation, nerve fiber layer defects, or disc hemorrhages) from a longitudinal study of glaucoma patients at the Glaucoma Center of the University of California–San Diego (La Jolla). Forty-seven eyes of 47 patients met the following inclusion/exclusion criterion: Each patient had at least 2 stereophotographs 2 or more years apart, and at least 1 reliable standard and 1 reliable SWAP examination within 6 months of each disc photograph in the same eye. The first stereophotograph that showed signs of progression that fulfilled the inclusion criterion was used. If there was no progression, the latest photograph from our longitudinal database was used. Additionally, patients with high refractive error (defined as $> \pm 5.00$ spherical equivalent or ± 3.00 cylinder), lens changes (defined as loss of > 1 line of visual acuity with a nuclear sclerotic cataract, or the development of any degree of posterior subcapsular cataract), or who underwent cataract extraction with or without trabeculectomy during the follow-up period were excluded.

VISUAL FIELDS

Standard perimetry was performed using the 24-2 full threshold algorithm using the commercially available Humphrey Field Analyzer (Humphrey-Zeiss, San Leandro, Calif). The Humphrey Field Analyzer was also used to perform SWAP examinations, in which a 440-nm narrowband size V blue stimulus is presented against a broadband 500- to 700-nm yellow background for 200 milliseconds to maximize spatial and temporal summation, further enhancing isolation of the short-wavelength-sensitive pathway.¹¹

All patients had at least 1 additional visual field for both SWAP and standard perimetry, prior to the baseline field and after the follow-up field, that confirmed the degree of visual field defect using the Ocular Hypertension Study visual field criteria for an abnormal field.¹⁷ Baseline and follow-up standard perimetry and SWAP visual fields closest to the time of the stereophotographs, were assessed using a clinical scoring system (CSS) and the Advanced Glaucoma Intervention Study (AGIS) scoring system. Using the CSS, visual field progression was based on the presence of at least 1 of the following criteria: (1) development of a new scotoma, defined as 2 adjacent points in a previously normal area at the .01 probability level on the pattern deviation plot, or 1 point within the central 10° that decline by 10 dB or more; (2) expansion of an existing scotoma, defined as 2 contiguous points adjacent to the scotoma that decline by 10 dB or more; or (3) deepening of an existing scotoma, defined as 2 points in the scotoma

that decline by 10 dB or more. Using AGIS, progression was defined as an increase in the AGIS score by greater than or equal to 4 points.¹⁸ Changes in standard perimetry and SWAP, using both AGIS and the CSS, were compared with progression detected by serial stereophotographs.

STEREOPHOTOGRAPHS

Simultaneous baseline and follow-up stereophotographs of each patient were graded for the presence of progression in a masked fashion by 2 experienced stereophotograph graders (C.A.G., E.Z.B.). A third experienced stereophotograph grader (R.N.W.) resolved all cases of disagreement. All graders were glaucoma specialists. Patients were divided into 2 groups: progressive and nonprogressive. Glaucomatous progression by stereophotographs was defined as either a decrease in the neuroretinal rim due to focal notching, undermining, or diffuse rim thinning, or the expansion of a preexisting nerve fiber layer defect or the development of a new nerve fiber layer defect. Changes in the neuroretinal rim and the parapapillary nerve fiber layer were determined by direct visual comparison of each quadrant of the disc. Measurements of disc area were obtained for each patient using a confocal scanning laser ophthalmoscope (Heidelberg Retinal Tomograph, Heidelberg Engineering, Heidelberg, Germany).

STATISTICAL ANALYSES

Statistical analyses were completed using JMP software (SAS Institute, Cary, NC). Differences between the progressed and nonprogressed groups were compared using a *t* test or χ^2 test. Comparisons of the mean change in AGIS scores using SWAP and standard perimetry in the progressed group were evaluated using a paired *t* test. The sensitivity, specificity, and the area under the receiver operating characteristic (ROC) curve were determined for each technique. The area under the ROC curve reflects the ability of a test to provide a result that corresponds with the dependant variable. A value of 1 is a perfect correlation, whereas a value of 0.5 indicates no correlation. A McNemar χ^2 test was used to compare the sensitivity and specificity found using each technique. To compare standard perimetry and SWAP with respect to sensitivity, patients who were deemed to have progressed (by stereophotographs) were tabulated according to whether standard perimetry and/or SWAP showed progression or stable disease, resulting in a 2×2 table. The McNemar χ^2 is calculated from this table in the usual manner. A similar table was prepared for patients deemed to have stable disease (by stereophotographs) and this was used to test the differences in specificity. The areas under the ROC curve for each technique were compared using the method of Delong et al,¹⁹ which uses the fraction of concordant pairs, with each tied pair counted as half. In a dichotomous classifying variable, the area under the ROC curve turns out to be equal to half the value of the sum of sensitivity and specificity. A *P* value of less than .05 was considered statistically significant.

were found to predict defects eventually detected with standard perimetry.^{13,16}

The purpose of the current study was to compare SWAP with standard perimetry for detection of progressive glaucomatous changes in the optic disc.

RESULTS

There was agreement between the initial 2 stereophotograph graders on identification of progression of glaucomatous optic disc damage by stereophotograph for 36

Table 1. Ocular Characteristics*

	Nonprogressed Patients (n = 25)	Progressed Patients (n = 22)	P
Mean change in pupil size, mm	-0.014 (1.25)	-0.045 (0.860)	.95
Mean sphere, D	-1.61 (2.15)	-1.85 (3.79)	.79
Mean cylinder, D	+1.17 (1.39)	+1.26 (0.89)	.90
Mean peak IOP, mm Hg	24.0 (5.8)	29.4 (11.3)	.04
Mean disc area, mm ²	2.56 (1.97)	2.02 (0.51)	.22
Baseline standard, mean deviation, dB	-2.96 (3.65)	-4.24 (4.92)	.31
Baseline standard, corrected pattern SD, dB	3.77 (4.38)	4.53 (4.21)	.55
Baseline vertical cup-disc ratio	0.69 (0.191)	0.75 (0.131)	.15

*Data are expressed as mean (SD) unless otherwise indicated. D indicates diopters; IOP, intraocular pressure.

(76%) of 47 subjects, with 15 (32%) graded as progressed, and 21 (45%) of 47 graded as nonprogressed. The 2 graders disagreed on the remaining 11 subjects (23%). Seven of these 11 subjects were considered progressed by the third grader, who resolved the cases of disagreement. Thus, a total of 22 patients (47%) were considered progressed by serial optic nerve stereophotographs, with 25 patients (53%) considered nonprogressed.

The ocular characteristics of both the progressed and nonprogressed groups are outlined in **Table 1**. The 2 groups did not differ significantly with respect to disc area, refraction, or the change in pupil size between the baseline and follow-up standard perimetry. The mean highest documented intraocular pressure in the ophthalmic record was 5.4 mm Hg higher in the progressed group than the nonprogressed group ($P < .04$). The disc area was smaller, and the baseline mean deviation and corrected pattern SD for standard perimetry and vertical cup-disc ratio were worse in the progressed group than in the nonprogressed group, but these differences were not statistically significant.

The baseline AGIS score for SWAP was slightly higher (mean, 2.5; SD, 2.8) than the baseline AGIS score for standard perimetry (mean, 2.3; SD, 2.7). However, this difference was not statistically significant ($P = .81$).

For the baseline fields, 5 patients had SWAP and standard perimetry prior to stereophotographs (average of 2.5 months for SWAP and 2.6 months for standard perimetry), and 42 patients had SWAP and standard perimetry after the stereophotographs (average of 1.6 months for SWAP and 1.3 months for standard perimetry). For the follow-up fields, 5 patients had SWAP prior to stereophotographs (average of 2.6 months), and 42 had SWAP after (average of 1.2 months). Twenty-six patients had standard perimetry prior to stereophotographs (average of 0.9 months) and 21 had it after (average of 1.4 months).

The patient characteristics of the progressed and nonprogressed groups are summarized in **Table 2**. There was no significant difference in mean age, sex, or race. Both groups were predominantly white. The average

Table 2. Patient Characteristics*

	Nonprogressed Patients (n = 25)	Progressed Patients (n = 22)	P
Age, y	64.3 (14.5)	66.9 (11.4)	.49
Sex			
Male	9 (36)	12 (55)	.20
Female	16 (64)	10 (45)	
Race			
White	21 (84)	17 (77)	.66
Black	1 (4)	3 (13)	
Asian	1 (4)	1 (5)	
Hispanic	2 (8)	1 (5)	
Mean follow-up period (range), y	4.2 (2.0-8.5)	4.0 (2.0-8.9)	.70

*Data are expressed as mean (SD) unless otherwise indicated.

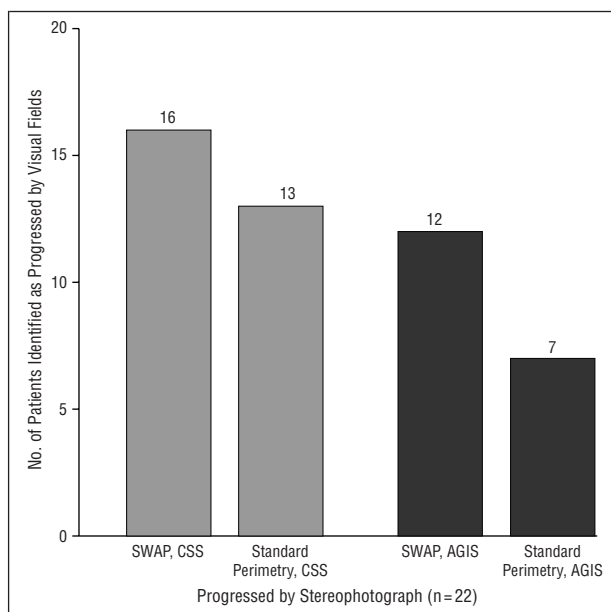


Figure 1. Number of patients with progressive optic disc cupping found to have progressed using visual fields. SWAP indicates short-wavelength automated perimetry; CSS, clinical scoring system; and AGIS, Advanced Glaucoma Intervention Study Criteria.

length of follow-up was 4.2 years (range, 2.0-8.9 years) for the nonprogressed group and 4.0 years (range, 2.0-8.9 years) for the progressed group. This difference was not significant.

Among eyes showing progression based on assessment of stereophotographs, the number of eyes progressed by each visual field test using both AGIS and CSS criteria is shown in **Figure 1**. The distribution of patients who demonstrated stable visual fields by each visual field test and the evaluation by each algorithm among eyes stable by photographic assessment is shown in **Figure 2**.

In the progressed group, standard perimetry showed progression in 7 (32%) of 22 patients while SWAP showed progression in 12 (55%) of 22 patients using AGIS criteria for visual field progression. The 2 types of visual fields agreed on the identification of progression for 6

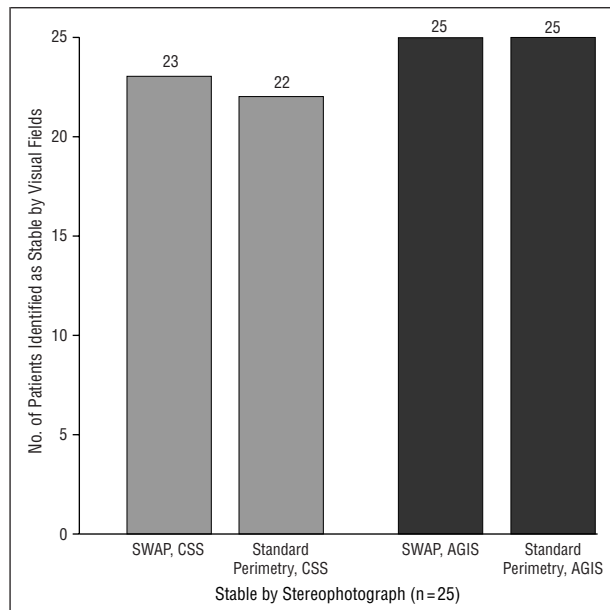


Figure 2. Number of patients with stable optic discs found stable using visual fields. SWAP indicates short-wavelength automated perimetry; CSS, clinical scoring system; and AGIS, Advanced Glaucoma Intervention Study Criteria.

patients. In the progressed group by photographic criteria, the mean difference in AGIS score was 4.53 (SD, 4.21) for SWAP and 3.62 (SD, 5.14) for standard perimetry, which was not statistically different ($P < .10$). In the nonprogressed group by photographic criteria, neither standard perimetry nor SWAP detected progressive field changes by AGIS criteria. In this group, the mean difference in AGIS score was 0.48 (SD, 0.96) for standard perimetry and 0.64 (SD, 0.75) for SWAP, which was not statistically different ($P < .44$). There was a statistically significant difference in the mean difference of AGIS scores for both standard perimetry ($P < .004$) and SWAP ($P < .001$) between the progressed and nonprogressed groups.

Using the CSS for visual field progression, standard perimetry progressed in 13 (59%) of 22 patients, while SWAP progressed in 16 (73%) of 22 patients in the progressed group by photographic criteria. Twelve patients were identified as progressed. In the nonprogressed group by photographic criteria, standard perimetry was stable in 22 (88%) of 25 patients, while SWAP was stable in 23 (92%) of 25 patients, with 20 patients identified as stable. Among patients identified as progressed by review of stereophotographs, SWAP identified more patients as progressed than did standard perimetry with each algorithm. The sensitivity and specificity for progression and the area under the ROC curve for each visual field technique evaluated by each algorithm are shown in **Table 3**. The sensitivity and specificity were judged for both visual field techniques compared with disc progression as demonstrated by stereophotographs. While the sensitivity, specificity, and the area under the ROC curve for detecting progression was higher with SWAP than with standard perimetry, this difference was significant only for the AGIS scoring system.

Table 3. Sensitivity and Specificity of Serial SWAP and Standard Perimetry Fields in the Detection of Stereophotograph-Defined Progression*

	CSS			AGIS Scoring System		
	SWAP	Standard Perimetry	P	SWAP	Standard Perimetry	P
Sensitivity	72.7	59.1	.38	54.5	33.8	.13
Specificity	92.0	88.0	1.00	100	100	1.00
Area under ROC curve	0.841	0.735	.19	0.773	0.659	.04

*Data are presented as percentages unless otherwise indicated. SWAP indicates short-wavelength automated perimetry; CSS, clinical scoring system; AGIS, Advanced Glaucoma Intervention Study; and ROC, receiver operator characteristic.

COMMENT

Our study compared baseline and follow-up standard perimetry and SWAP in glaucoma patients who had stable baseline and follow-up optic nerve stereophotographs with those patients with progressive glaucomatous change documented with stereophotography, using 2 different scoring algorithms for visual field progression.

The rate of progression defined by stereophotographs in our study was 46.8%. The mean duration of follow-up was 4.1 years (range, 2.0-8.9), yielding a rate of progression of 11.4% per year. Previously published reports have estimated a 7% per year rate of progression based on serial stereophotographs.^{20,21} Ours was not a population study but a study of higher-risk individuals, so meaningful information regarding rates of progression cannot be generalized to a more diverse population.

Using both the AGIS and CSS, SWAP showed a higher sensitivity for progressive optic disc changes than standard perimetry, without loss of specificity, and thus a larger area under the ROC curve. However, this difference was only statistically significant using the AGIS scoring system.

Evaluation using the CSS with SWAP showed the highest sensitivity at 72.7%, with a specificity of 92% and the largest area under the ROC curve (0.841) (Table 3). The relatively low sensitivity of both types of visual fields to stereophotograph-defined changes in the optic disc is consistent with previous reports of structural changes occurring without demonstrable functional defects.^{22,23} This supports the hypothesis that large numbers of ganglion cell populations may lose function before detection of progression is possible by standard perimetry.²⁴ However, it is important to emphasize that there is no "gold standard" in evaluating progression in glaucoma and that evaluation of optic disc stereophotographs to assess progression is subject to interexaminer interpretation.²⁵

While both standard perimetry and SWAP showed statistically significant differences in the mean differences in AGIS scores between the progressed and nonprogressed groups, the mean change in AGIS scores was higher in SWAP than in standard perimetry. How-

ever, this result did not achieve statistical significance ($P < .11$).

Using the AGIS scoring system, neither standard perimetry nor SWAP detected progression in the non-progressed group based on photographic assessment. With the CSS, SWAP detected progression in 2 patients while standard perimetry detected progression in 3 in the nonprogressed group. Thus, while the CSS showed a higher sensitivity for the detection of structural changes, it was less specific than the AGIS scoring system. This probably reflects a more lax cut-off criterion for progression in the CSS compared with the AGIS scoring system. However, it is also possible that the lower specificity of the CSS is due to changes in visual function that may have occurred prior to observable changes in optic disc structure.

The redundancy inherent in the visual system due to multiple subpopulations of ganglion cells with overlapping receptive fields may provide one explanation for the lack of sensitivity of standard perimetry to detect early axonal loss in glaucoma. Different ganglion cell types respond to specific, yet overlapping, components of the visual image and project this information along distinct interconnected visual channels, at least at the level of the lateral geniculate nucleus.²⁶ Standard perimetry stimulates several of these visual channels simultaneously. By developing selective stimuli to target specific ganglion cell populations, the responses of an isolated visual channel may be maximized and consequently may provide a more sensitive test to detect axonal loss in glaucoma.²⁷

Short-wavelength automated perimetry is used in clinical practice to detect early glaucomatous damage. Both standard perimetry and SWAP have been shown to correlate with structural changes of the optic disc.²⁸⁻³² One study demonstrated a higher correlation between structural changes demonstrated by scanning laser ophthalmoscopy in early glaucoma and the mean deviation of SWAP than for the mean deviation of standard perimetry.³³ Additionally, defects detected using SWAP tended to be deeper and more extensive than defects found with standard perimetry. Two 5-year prospective studies performed independently have each found that functional deficits demonstrated with SWAP in some patients with ocular hypertension and glaucoma are detectable several years earlier than with standard perimetry and, thus, may predict the development of functional loss with standard perimetry.^{14,34}

This increased sensitivity might provide a better marker for progression and thus show a higher correlation with structural changes in the optic nerve over time. On the other hand, increased variability,³⁵ greater sensitivity to cataractous changes of the crystalline lens,³⁶ and loss of the smaller subpopulation of bistratified ganglion cells in extremely advanced disease might limit the usefulness of SWAP in the detection of progressive glaucomatous damage.

These previous studies have compared progressive scotomas using SWAP with those using standard perimetry. To evaluate the ability of visual function tests such as standard perimetry and SWAP to detect progression

in glaucoma, these tests should be compared with structural changes of the optic disc.

In summary, this study has demonstrated that serial SWAP corresponded better than serial standard perimetry with glaucomatous changes of the optic disc, yielding a higher sensitivity and similar specificity. Using the AGIS scoring system, there was a significant difference in the area under the ROC curve between standard perimetry and SWAP. This evidence seems to indicate that serial SWAP may improve the detection of glaucomatous progression. However, a larger study population and evaluation of new progression algorithms are required to determine if there is a clinically significant difference between standard perimetry and SWAP using all grading algorithms.

Accepted for publication February 11, 2000.

This study was supported in part by grant NEI EY08208 from the National Eye Institute, National Institutes of Health, Bethesda, Md (Dr Sample), the Glaucoma Research Foundation, San Francisco, Calif (Dr Sample), grant EY11008 from the National Eye Institute, National Institutes of Health, Bethesda, Md (Dr Zangwill), the Heed Ophthalmic Foundation, Chicago, Ill (Dr Girkin), and the Joseph Drown Foundation, Los Angeles, Calif (Dr Weinreb).

Presented in part at the annual meeting of the Association of Research and Vision and Ophthalmology, Ft Lauderdale, Fla, May 1999.

Corresponding author: Robert N. Weinreb, MD, Glaucoma Center, University of California—San Diego, 9500 Gilman Dr, La Jolla, CA 92093-0946 (e-mail: weinreb@eyecenter.ucsd.edu).

REFERENCES

1. Lichten PR. Variability of expert observers in evaluating the optic disc. *Trans Am Ophthalmol Soc.* 1977;74:532-572.
2. Zangwill L, Shakiba S, Caprioli J, Weinreb RN. Agreement between clinicians and a confocal scanning laser ophthalmoscope in estimating cup/disk ratios. *Am J Ophthalmol.* 1995;119:415-421.
3. Weinreb RN. Assessment of optic disc topography for diagnosing and monitoring glaucoma [editorial]. *Arch Ophthalmol.* 1998;116:1229-1231.
4. Zeyen TG, Caprioli J. Progression of disc and field damage in early glaucoma. *Arch Ophthalmol.* 1993;111:62-65.
5. Werner EB, Petrig B, Krupin T, Bishop KI. Variability of automated visual fields in clinically stable glaucoma patients. *Invest Ophthalmol Vis Sci.* 1989;30:1083-1089.
6. Johnson CA, Nelson-Quigg JM. A prospective three-year study of response properties of normal subjects and patients during automated perimetry. *Ophthalmology.* 1993;100:269-274.
7. Werner EB, Krupin T, Adelson A, Feitl ME. Effect of patient experience on the results of automated perimetry in glaucoma suspect patients. *Ophthalmology.* 1990;97:44-48.
8. Guthauser U, Flammer J. Quantifying visual field damage caused by cataract. *Am J Ophthalmol.* 1988;106:480-484.
9. Lindenmuth KA, Skuta GL, Rabbani R, Musch DC. Effects of pupillary constriction on automated perimetry in normal eyes. *Ophthalmology.* 1989;96:1298-1301.
10. Advanced Glaucoma Intervention Study 2: visual field test scoring and reliability. *Ophthalmology.* 1994;101:1445-1455.
11. Sample PA, Weinreb RN. Color perimetry for assessment of primary open-angle glaucoma. *Invest Ophthalmol Vis Sci.* 1990;31:1869-1875.
12. Martin PR, White AJ, Goodchild AK, Wilder HD, Sefton AE. Evidence that blue-on cells are part of the third geniculocortical pathway in primates. *Eur J Neurosci.* 1997;9:1536-1541.
13. Sample PA, Weinreb RN. Progressive color visual field loss in glaucoma. *Invest Ophthalmol Vis Sci.* 1992;33:2068-2071.
14. Johnson CA, Adams AJ, Casson EJ, Brandt JD. Blue-on-yellow perimetry can

- predict the development of glaucomatous visual field loss. *Arch Ophthalmol.* 1993; 111:645-650.
15. Sample PA, Weinreb RN. Standard achromatic perimetry vs. short-wavelength automated perimetry for following glaucoma. In: GK K, ed. *Glaucoma Update V.* Germany: Springer Verlag; 1995:197-204.
 16. Johnson CA, Adams AJ, Casson EJ, Brandt JD. Progression of early glaucomatous visual field loss as detected by blue-on-yellow and standard white-on-white automated perimetry. *Arch Ophthalmol.* 1993;111:651-656.
 17. Kass M. The Ocular Hypertension Treatment Study. *J Glaucoma.* 1994;3:97-100.
 18. The Advanced Glaucoma Intervention Study (AGIS) 1: study design and methods and baseline characteristics of study patients. *Control Clin Trials.* 1994;15: 299-325.
 19. DeLong ER, DeLong DM, Clarke-Pearson DL. Comparing the areas under two or more correlated receiver operating characteristic curves: a nonparametric approach. *Biometrics.* 1988;44:837-845.
 20. Airaksinen PJ, Tuulonen A, Alanko HI. Rate and pattern of neuroretinal rim area decrease in ocular hypertension and glaucoma. *Arch Ophthalmol.* 1992;110: 206-210.
 21. Prum BE Jr. Evaluation of progressive structural damage in glaucoma. *Chibret Int J Ophthalmol.* 1994;60-67.
 22. Sommer A, Katz J, Quigley HA, et al. Clinically detectable nerve fiber atrophy precedes the onset of glaucomatous field loss. *Arch Ophthalmol.* 1991;109: 77-83.
 23. Sommer A, Pollack I, Maumenee AE. Optic disc parameters and onset of glaucomatous field loss. I: methods and progressive changes in disc morphology. *Arch Ophthalmol.* 1979;97:1444-1448.
 24. Quigley HA, Addicks EM, Green WR. Optic nerve damage in human glaucoma, III: quantitative correlation of nerve fiber loss and visual field defect in glaucoma, ischemic neuropathy, papilledema, and toxic neuropathy. *Arch Ophthalmol.* 1982;100:135-146.
 25. Coleman AL, Sommer A, Enger C, et al. Interobserver and intraobserver variability in the detection of glaucomatous progression of the optic disc. *J Glaucoma.* 1996;5:384-389.
 26. Schiller PH, Logothetis NK. The color-opponent and broad-band channels of the primate visual system. *Trends Neurosci.* 1990;13:392-398.
 27. Sample PA, Bosworth CF, Weinreb RN. Short-wavelength automated perimetry and motion automated perimetry in patients with glaucoma. *Arch Ophthalmol.* 1997;115:1129-1133.
 28. Teesalu P, Vihanninjoki K, Airaksinen PJ, Tuulonen A. Hemifield association between blue-on-yellow visual field and optic nerve head topographic measurements. *Graefes Arch Clin Exp Ophthalmol.* 1998;236:339-345.
 29. Yamagishi N, Anton A, Sample PA, et al. Mapping structural damage of the optic disk to visual field defect in glaucoma. *Am J Ophthalmol.* 1997;123:667-676.
 30. Weinreb RN, Shakiba S, Sample PA, et al. Association between quantitative nerve fiber layer measurement and visual field loss in glaucoma. *Am J Ophthalmol.* 1995;120:732-738.
 31. Bathija R, Zangwill L, Berry CC, Sample PA, Weinreb RN. Detection of early glaucomatous structural damage with confocal scanning laser tomography. *J Glaucoma.* 1998;7:121-127.
 32. Anton A, Yamagishi N, Zangwill L, Sample PA, Weinreb RN. Mapping structural to functional damage in glaucoma with standard automated perimetry and confocal scanning laser ophthalmoscopy. *Am J Ophthalmol.* 1998;125:436-446.
 33. Teesalu P, Vihanninjoki K, Airaksinen PJ, Tuulonen A, Laara E. Correlation of blue-on-yellow visual fields with scanning confocal laser optic disc measurements. *Invest Ophthalmol Vis Sci.* 1997;38:2452-2459.
 34. Sample PA, Taylor JD, Martinez GA, Lusky M, Weinreb RN. Short-wavelength color visual fields in glaucoma suspects at risk. *Am J Ophthalmol.* 1993;115: 225-233.
 35. Wild JM, Cubbidge RP, Pacey IE, Robinson R. Statistical aspects of the normal visual field in short-wavelength automated perimetry. *Invest Ophthalmol Vis Sci.* 1998;39:54-63.
 36. Sample PA, Johnson CA, Haegerstrom-Portnoy G, Adams AJ. Optimum parameters for short-wavelength automated perimetry. *J Glaucoma.* 1996;5:375-383.

Notes From Our Ophthalmic Heritage

A look at the past . . .

Listerine in Diseases of the Eye and Ear

Purulent Conjunctivitis

If the period of active pus formation has continued for two days or more, the undiluted LISTERINE may be dropped into the eye every four hours. In those forms observed in infants showing a tendency to the formation of pseudo-membrane, LISTERINE is specially valuable and of great service in all cases of mucopurulent or Purulent Conjunctivitis, preceded by the cleansing of the membrane with a solution of chloride of sodium.

Granular Eye-Lids

A weak solution of LISTERINE affords great relief from the heated, burning sensation.

The scaly, sandy exfoliation of the margins of the lids, and the shedding of eye-lashes is checked, and the constant succession of minute styes arrested.

Reference: Keating JM. *Listerine in Special Practice.* 1894.